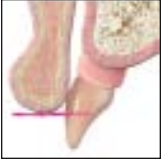



The Lip-Tooth-Ridge Classification: A Guidepost for Edentulous Maxillary Arches. Diagnosis, Risk Assessment, and Implant Treatment Indications



Adrien Pollini, DDS¹
Jack Goldberg, DDS, MS²
Ricardo Mitrani, DDS, MSD^{2,3}
Dean Morton, DDS, MSD⁴

Prosthetic rehabilitation of the edentulous maxilla is known to be challenging and requires meticulous planning. The purpose of this article is to describe a novel classification system, the Lip-Tooth-Ridge (LTR), that offers a guidepost for treatment planning the edentulous maxilla for fixed or removable prostheses. This tool will help clinicians identify the final prosthetic design and will provide a case-specific risk assessment guide regarding two different areas. A high (HER) or low (LER) esthetic risk will be determined based on lip dynamics, as well as a high or low structural risk according to the prosthetic space availability. Int J Periodontics Restorative Dent 2017;37:835–841. doi: 10.11607/prd.3209

Prosthetic rehabilitation of the edentulous maxilla is known to be challenging and requires meticulous planning.¹ This is mainly due to anatomical characteristics, bone resorption pattern, quality of bone, development of prosthetic emergence profile,² oral hygiene limitations, influence of the teeth and hard tissue during speech, and the importance of the prosthesis for facial and dental esthetics.^{3,4} Zitzmann and Marinello³ reviewed the literature and provided implant restorative guidelines for the edentulous maxilla. Simon and Raigrodski⁵ provided a classification of the types of residual ridge deficiencies and addressed the need for gingival prostheses. Bidra and Agar⁶ classified the patients into four categories based on the amount of tissue loss, the position of the anterior teeth in relation to the residual ridge, lip support, smile line, and need for gingiva-colored prosthetic material. This classification is intended exclusively for fixed prostheses; consequently, the anterior teeth are positioned relative to the patient's ridge configuration.

It is the purpose of this article to describe a novel classification system, the Lip-Tooth-Ridge (LTR), that offers a guidepost for treatment planning the edentulous maxilla for fixed or removable prostheses. This tool will help clinicians identify the

¹Resident and Graduate Student, Advanced Education in Prosthodontics, Department of Oral Health and Rehabilitation, School of Dentistry, University of Louisville, Louisville, Kentucky, USA; Assistant Professor, Laval University, Quebec City, Canada.

²Private Practice, Mexico City, Mexico.

³Affiliate Associate Professor, Department of Restorative Dentistry, University of Washington. Seattle, Washington, USA; Resident Faculty, Spear Education, Scottsdale, Arizona, USA.

⁴Professor and Chair, Department of Prosthodontics, Indiana University School of Dentistry, Indianapolis, Indiana, USA.

Correspondence to: Dr Adrien Pollini, 2420 rue de la Terrasse, Pavillon de médecine dentaire, local 1615, Ville de Québec, QC G1V 0A6, Canada.
Email: adrien.pollini@gmail.com

©2017 by Quintessence Publishing Co Inc.

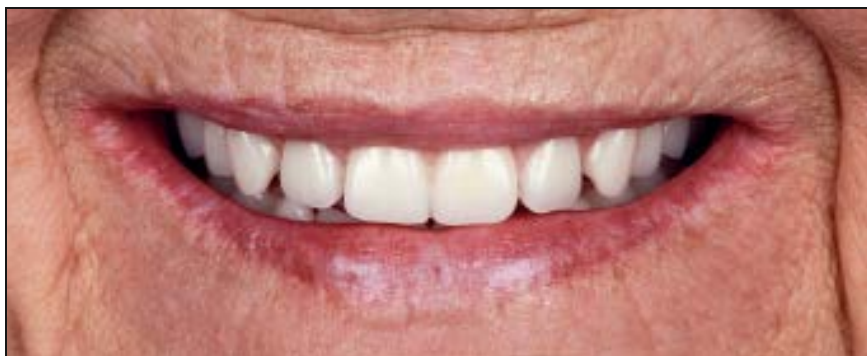

Fig 1 Anterior tooth set-up featuring adequate midline position and harmonious relationship between the smile line, the lower lip, and the labial commissures.

final prosthetic design and will provide a case-specific risk assessment guide.

Classification Factors

The LTR classification is based on the relationship between the optimal dimensions and position of the maxillary central incisor, the dimensions and dynamics of the maxillary lip, and the architecture of the edentulous ridge.

Tooth Position

The maxillary incisal edge position is considered the starting point of any maxillary reconstruction.^{7,8} It is determined by analyzing dentofacial esthetics, tooth proportion, phonetics, and the kinetics of the lower lip.^{9–14} This landmark is the keystone for developing the occlusal plane and the vertical dimension of occlusion.¹² After proper positioning of the maxillary central incisor's incisal edge, its inclination should not be set according to any opposing tooth

position nor to contact the residual ridge (unpleasant and artificial-looking esthetic outcomes associated with denture teeth placed too apical and palatal have been described in the literature¹³). The buccolingual position and the inclination of the six maxillary anterior teeth are conducted following a facially generated smile assessment⁸ (Fig 1).

For the purpose of this article, the esthetic zone is described as the visible area shown on exaggerated smile, and it varies dramatically from patient to patient.

During the smile design process, the curvature of the lower lip should be used as an anatomical reference to determine the position of the maxillary teeth. The literature provides extensive clinical guidelines regarding the midline position and the relationship between the upper lip and the zeniths of the maxillary teeth.^{15–17} Since the resorptive process of the maxillary ridge is also affected posteriorly, care should be taken to assess posterior tooth position and ensure an adequate fill of the buccal corridors.^{17,18}

Lip

The upper lip position is one of the most important elements in anterior esthetics; its static and dynamic assessment will play a crucial role in deciding the type of prosthetic design for the patient. Based on the upper lip position, Tjan et al¹⁹ classified the smile for dentate patients as high, medium, or low, with medium and high corresponding to 80% of the population. With a medium smile, the maxillary lip moves apically (at full smile) to the maxillary central incisors' and canines' gingival levels. The use of video in addition to photography has been shown to be more effective in capturing the most apical position of the upper lip on maximum smile.²⁰ This diagnostic tool proves that a vast number of individuals are potentially at risk, which is not evident using still photography.

Another important subjective element related to facial esthetics is the determination of adequate maxillary lip support or lip projection. Lip projection at its apex is related to lip thickness and to support provided by the maxillary alveolar process and anterior teeth. Ideal lip support is a (subjective) range, and its assessment and perception are affected by multiple factors. Furthermore, the inclination of the maxillary incisors with respect to the frontal plane affects lip support.^{21,22} The assessment of this parameter will influence the selection of a prosthetic design including or excluding a labial extension, also called a flange. This should be evaluated at rest and during function on profile

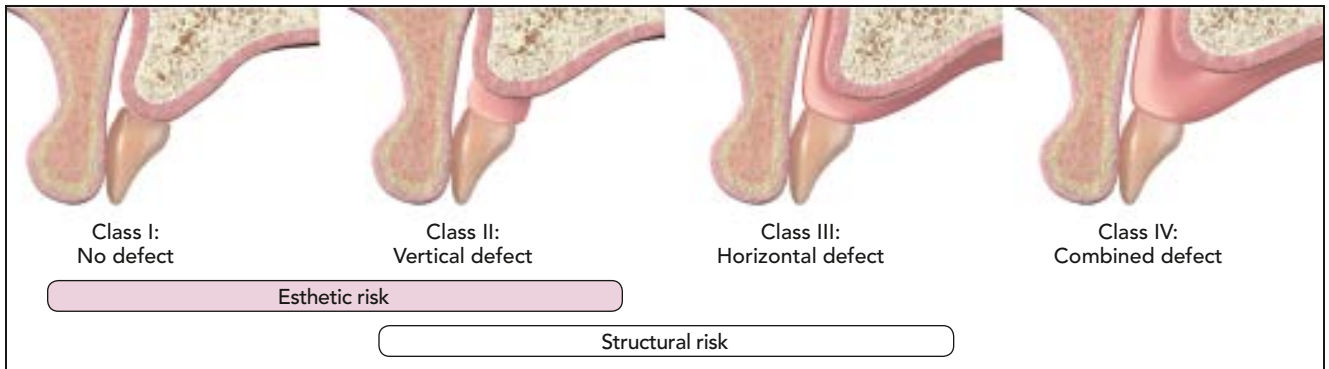


Fig 2 The LTR classification. Visual representation of the four major indications related to the maxillary complete edentulous situation. Note that the classification is based on the defect present between the ridge and the lip horizontally and the prosthetic tooth and the ridge vertically. The bone availability for implant placement does not influence the type of indication.

and frontal views^{23,24} and compared with a flangeless design. A thick lip phenotype will overcome many deficiencies in the prosthetic design selected by the clinician.²⁵ Therefore, any patient presenting a thin upper lip should be considered a high esthetic risk irrespective of the type of definitive restoration selected. The patient should be educated about existing anatomical limitations and allowed to make the final decision on what is considered an acceptable lip support through a trial period.

Ridge

Vertical and horizontal bone resorption of the residual alveolar ridge has been described to occur after complete extraction of the maxillary teeth.^{26–28} However, this resorption pattern has been described in complete denture patients after 5 to 25 years. The residual ridge undergoes a primary resorption that occurs mostly during the first 6 months after extraction and a continuous, steady resorption over the years.^{29,30}

If surgical procedures are performed to preserve or augment the dimension of the ridge crest at the time of extraction³¹ and no removable complete denture is worn, the amount of alveolar ridge resorption can be expected to be significantly less.^{29,30} The alveolar bone level and status of the buccal plate around the teeth to be extracted will also influence the amount of postextraction resorption.^{29,30} In other words, the fact that a patient presents with a maxillary removable complete denture does not necessarily imply that a labial prosthesis extension is mandatory. At the same time, adequate prosthetic space may not be available to allow all types of prosthetic designs. The lip support will be affected by the alveolar ridge resorption irrespective of its magnitude and loss of tooth structure. However, this lack of support is not necessarily related to bone availability for implant placement.

Milinkovic and Cordaro³² demonstrated in a recent systematic review that horizontal bone grafts and LeFort surgery on edentulous

patients (regardless of the surgical procedure performed) present unpredictable outcomes when providing lip support in cases of transition from an overdenture to a fixed restoration. Depending on the amount of bone resorption and the desired prosthetic design, the residual ridge geometry may need to be modified to ensure a convex emergence profile that will prevent food entrapment and promote appropriate oral hygiene procedures compatible with sustainable oral health.³³

The main objective behind this classification is to provide the interdisciplinary treatment team with a graphic and comprehensive vision of the patient's condition. Based on this, the available prosthetic solutions and materials can be scrutinized, as opposed to having one prosthetic solution for all patients.

The LTR classification integrates two fundamental processes. The first intends to categorize the patient into one of four possible clinical scenarios based on the deficiency of hard and soft tissue between the ridge and the teeth in a

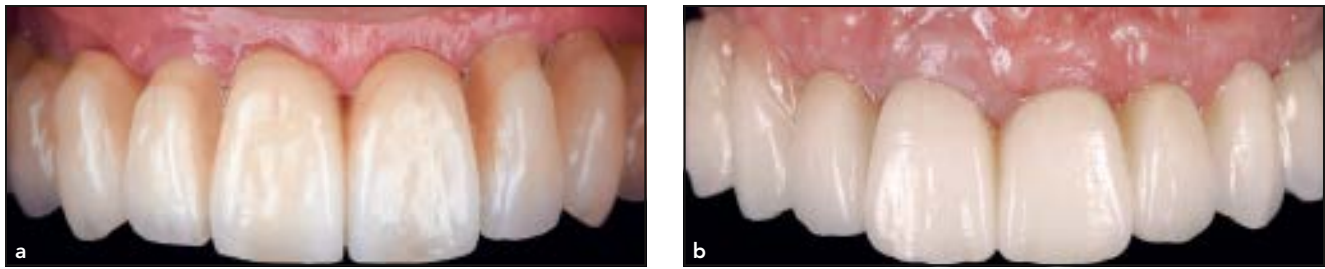


Fig 3 Conventional crown and bridge designs. (a) Metal-ceramic. (b) Zirconia-ceramic.

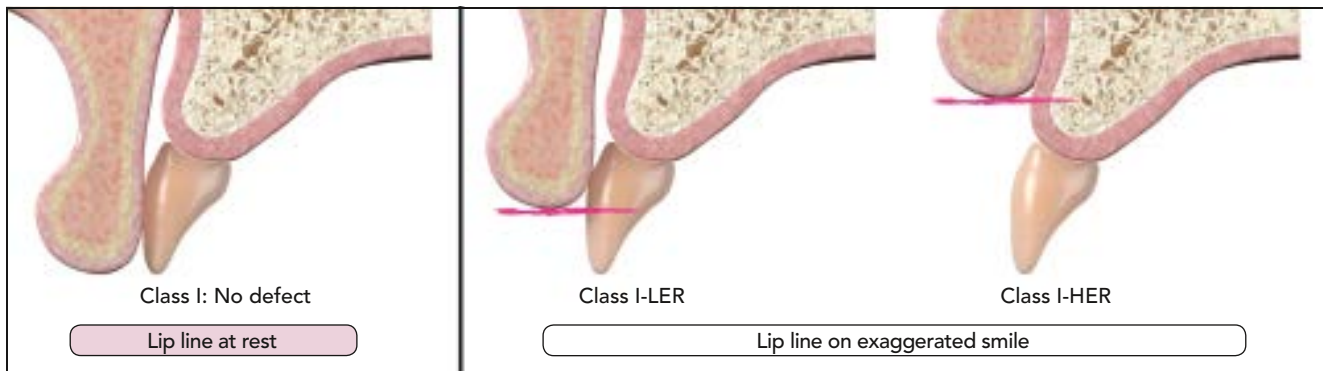


Fig 4 Class I-LER and -HER. Note that on exaggerated smile, the lip line is above the prosthesis/ridge transition in the HER category.

vertical aspect and between the ridge and lip in a horizontal aspect (Fig 2). The second process consists of carrying out a risk assessment in two different areas. The first area relates to the esthetic risk and consists of incorporating the relevance of lip dynamics into the decision process. For this assessment, two scenarios should be considered: (1) lip mobility that poses a high esthetic risk (HER) such that the transition line between the prosthesis and the ridge is exposed, and (2) lip mobility that does not expose such a transition line (low esthetic risk [LER]). The second area relates to the structural risk. For any given prosthetic design, space availability plays an important role. Having inadequate space may lead to biomechanical failure. Here, two scenarios should be considered: (1) high structural risk (HSR),

which is present when inadequate space for components and materials is available, and (2) low structural risk (LSR), where patients present appropriate space.

LTR Classifications

Class I

This clinical condition poses the ideal scenario for a conventional implant-supported "crown and bridge" prosthesis. It is characterized by minimal tissue deficiency (the cervical margin of the proposed maxillary central incisor emerges straight from the soft tissue, mimicking a tooth-supported restoration; no gingival prosthetic material is needed (Fig 3). This implant-supported prosthesis is commonly fabricated using metal-

ceramics, although zirconia can be used as well (Fig 3b). Adequate connector sizes are critical (at least 7 to 10 mm of vertical prosthetic space, based on the type of retention selected). The vertical prosthetic space extends from the platform of a bone-level implant to the occlusal surface of the restoration. In maxillary edentulous situations, the healing pattern occurring after multiple tooth extractions leads to a flat ridge configuration. The development of a scalloped soft tissue contour is not predictable, and the use of bone and soft tissue augmentation techniques will provide suboptimal outcomes in the interproximal areas. Therefore, achieving a harmonious relationship between the tooth structure and the underlying soft tissue will require creating an illusion through a prosthetic compen-

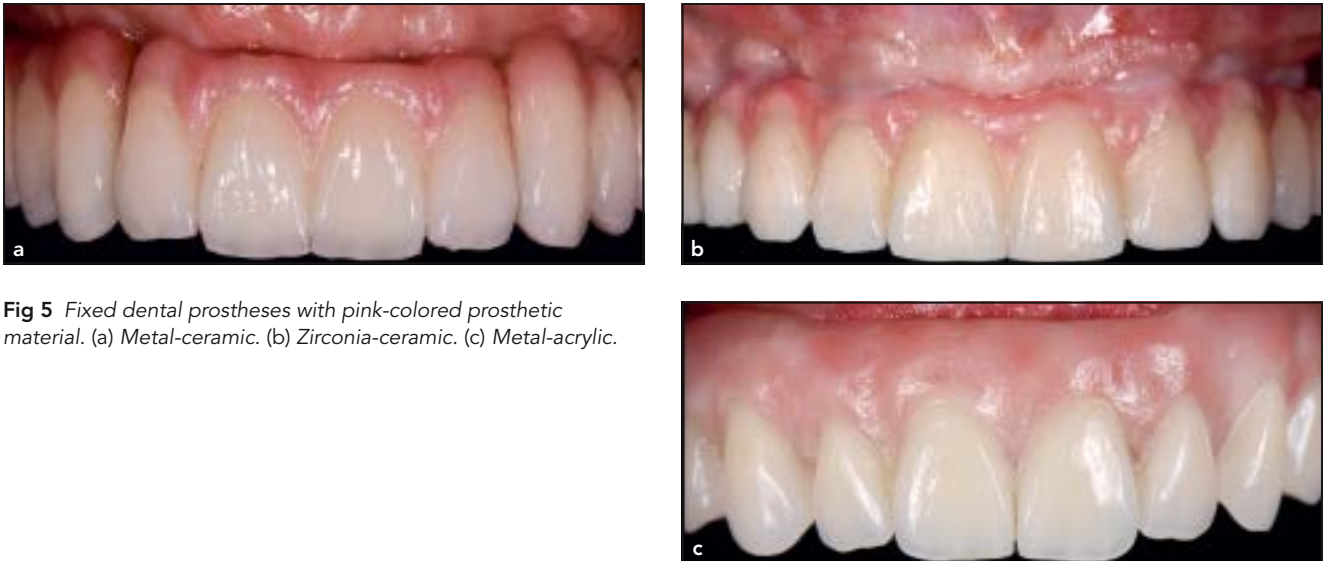


Fig 5 Fixed dental prostheses with pink-colored prosthetic material. (a) Metal-ceramic. (b) Zirconia-ceramic. (c) Metal-acrylic.

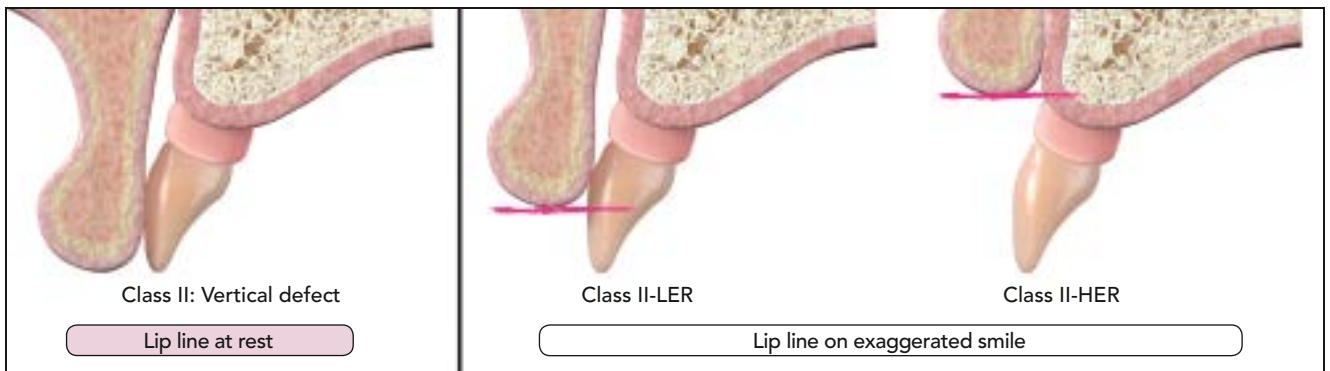


Fig 6 Class II-LER and -HER. Note that on exaggerated smile, the lip line is above the prosthesis/ridge transition in the HER category.

sation, such as long contact areas and/or the ceramic characterization of the gingival embrasures.

For Class I-LER, the management of interdental papillae still poses a challenge as 87% of dentate patients presenting low lip line still show interdental papillae on exaggerated smile³⁴ (Fig 4).

Conversely, Class I-HER presents an increased esthetic risk due to greater soft tissue display. Adequate soft-tissue grooming should be executed, and in certain cases, interdental gingival prosthetic material may be used (Fig 4).

Class II

This clinical condition consists of a larger vertical deficiency between the cervical margin of the proposed maxillary central incisor and the alveolar ridge, and it requires pink-colored prosthetic material (ceramic, composite, or acrylic) This type of prosthesis can be fabricated using metal-ceramics (Fig 5a), zirconia-ceramics (Fig 5b), or metal-acrylic (Fig 5c). The metal-ceramic and zirconia-ceramic designs will require an average of 8 to 12 mm and the metal-acrylic 13 to 15 mm in the pos-

terior area. The Class II-HER (Fig 6) represents an esthetic risk because the junction between the prosthesis and the residual ridge will need to be hidden under the upper lip position on exaggerated smile. This requires precise presurgical planning and a surgical template to ensure that adequate bone reduction is performed.

If anatomical structures limit the removal of bone for prosthetic/esthetic needs, an alternative design needs to be considered, such as distally tilted implants, alternative implant distribution, or the use of

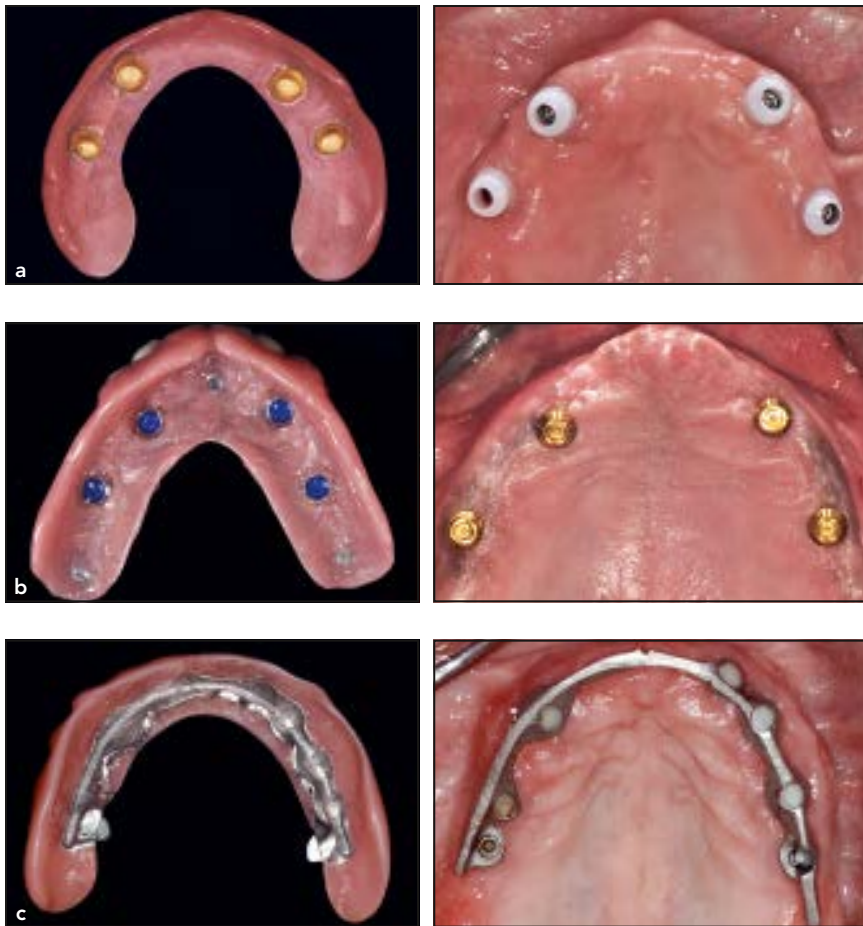


Fig 7 Overdentures retained by (a) telescope attachments, (b) Locator attachments, and (c) a bar.

zygomatic implants, to bypass the anatomical limitation and/or lack of sufficient bone for implant placement.

Class III

This clinical situation represents a tissue deficiency primarily with a horizontal component, causing inadequate lip support (Fig 2). Hence, it warrants treatment with a removable prosthesis including a labial extension (flange). Such prostheses (overdentures) can be retained by **telescope (Fig 7a) or**

Locator attachments (Fig 7b) (Zest).

The minimal vertical space required for these prosthetic design is larger compared to that for a Class I, ranging from **11 to 12 mm** depending on the system selected. A bar-type overdenture may not be recommended for this clinical scenario due to vertical space constraints.

While Class III can be converted to Class IV by means of an osteotomy, anatomical limitations such as a floor of the nose and/or sinus should be taken into account in cases where such bone reduction is not a viable option. The limited vertical space precludes the use

of a fixed detachable prosthesis. If such a prosthetic design is used, a structurally weak prosthesis will result and will eventually lead to bio-mechanical complications.

Class IV

This clinical situation involves a substantial residual defect (with vertical and horizontal components) with inadequate lip support (Fig 2), warranting a removable prosthesis with a labial extension (flange) with the option of using either the aforementioned prosthetic design for Class III or a bar type overdenture (Fig 7c). If a fixed detachable prosthesis is used for this clinical condition, oral hygiene access will be compromised due to a buccal shelf and long-term maintenance of the implants will be at risk, possibly leading to biologic complications.

Discussion

Space constraints have long been a problem in restorative dentistry. This predicament can be addressed by increasing vertical dimension or by means of surgical bone reduction. It should be noted that both alternatives have limitations: esthetic, biologic, and/or structural.

Bone removal to create optimal space is done routinely but should be cautiously examined. The high biologic cost of removing sound hard tissue in the name of space optimization for a certain prosthetic design has to be well understood and explained to the patient.

Preoperative evaluation of the patient's existing condition should be a comprehensive exercise. By doing this, the interdisciplinary treatment team can objectively choose the best and most conservative option based on the patient's specific anatomical characteristics. While modifying these characteristics to fit a certain restorative design may provide financial benefits, it may incur high biologic costs along the way.

Conclusions

This classification system is intended to offer the interdisciplinary team a comprehensive and graphic tool to identify the patient condition and the potential solutions available. No hierarchical distinction is made between esthetic and functional risks, as both can lead to irreversible failure.

Acknowledgments

The authors reported no conflicts of interest related to this study.

References

- Desjardins RP. Prosthesis design for osseointegrated implants in the edentulous maxilla. *Int J Oral Maxillofac Implants* 1992;7:311–320.
- Schnitman PA. The profile prosthesis: An aesthetic fixed implant-supported restoration for the resorbed maxilla. *Pract Periodontics Aesthet Dent* 1999;11:143–151.
- Zitzmann NU, Marinello CP. Fixed or removable implant-supported restorations in the edentulous maxilla: Literature review. *Pract Periodontics Aesthet Dent* 2000;12:599–608.
- Taylor TD. Fixed implant rehabilitation for the edentulous maxilla. *Int J Oral Maxillofac Implants* 1991;6:329–337.
- Simon H, Raigrodski AJ. Gingiva-colored ceramics for enhanced esthetics. *Quintessence Dent Technol* 2002;25:155–172.
- Bidra AS, Agar JR. A classification system of patients for esthetic fixed implant-supported prostheses in the edentulous maxilla. *Compend Contin Educ Dent* 2010;31:366–370.
- Spear FM, Kokich VG, Mathews DP. Interdisciplinary management of anterior dental esthetics. *J Am Dent Assoc* 2006;137:160–169.
- Lombardi RE. The principles of visual perception and their clinical application to denture esthetics. *J Prosthet Dent* 1973;29:358–382.
- Vig RG, Brundo GC. The kinetics of anterior tooth display. *J Prosthet Dent* 1978;39:502–504.
- Pound E. Utilizing speech to simplify a personalized denture service. *J Prosthet Dent* 1970;24:586–600.
- Robinson SC. Physiological placement of artificial anterior teeth. *J Can Dent Assoc (Tor)* 1969;35:260–266.
- Silverman MM. The speaking method in measuring vertical dimension. 1952. *J Prosthet Dent* 2001;85:427–431.
- Frush JP, Fisher RD. The dynesthetic interpretation of the dentogenic concept. *J Prosthet Dent* 1958;8:558–581.
- Ash MM Jr, Nelson SJ. *Wheeler's Dental Anatomy, Physiology, and Occlusion*, ed 8. Philadelphia: Saunders, 2003:13.
- Rufenacht CR. *Fundamentals of Esthetics*. Berlin: Quintessence, 1990.
- Goldstein RE. *Esthetics in Dentistry*. Philadelphia: Lippincott, 1976.
- Dong JK, Jin TH, Cho HW, Oh SC. The esthetics of a smile: A review of some recent studies. *Int J Prosthodont* 1999;12:9–19.
- Choi TR, Jin TH, Dong K. A study on the exposure of maxillary and mandibular central incisor in smiling and physiologic rest position. *J Wonkwang Dent Res Inst* 1995;5:371–379.
- Tjan AH, Miller GD, The JG. Some esthetic factors in a smile. *J Prosthet Dent* 1984;51:24–28.
- Van Der Geld P, Oosterveld P, Berge SJ, Kuijpers-Jagtman AM. Tooth display and lip position during spontaneous and posed smiling in adults. *Acta Odontol Scand* 2008;66:207–213.
- Sarver DM. *Esthetic Orthodontics and Orthognathic Surgery*. St. Louis: Mosby, 1998.
- Arnett GW, Bergman RT. Facial keys to orthodontic diagnosis and treatment planning. Part I. *Am J Orthod Dentofacial Orthop* 1993;103:299–312.
- Proffit WR, Phillips C, Douvartzidis N. A comparison of outcomes of orthodontic and surgical-orthodontic treatment of Class II malocclusion in adults. *Am J Orthod Dentofacial Orthop* 1992;101:556–565.
- McNamara L, McNamara JA Jr, Ackerman MB, Baccetti T. Hard- and soft-tissue contributions to the esthetics of the posed smile in growing patients seeking orthodontic treatment. *Am J Orthod Dentofacial Orthop* 2008;133:491–499.
- Scott CR, Goonewardene MS, Murray K. Influence of lips on the perception of malocclusion. *Am J Orthod Dentofacial Orthop* 2006;130:152–162.
- Carlsson GE, Bergman B, Hedegård B. Changes in contour of the maxillary alveolar process under immediate dentures. A longitudinal clinical and x-ray cephalometric study covering 5 years. *Acta Odontol Scand* 1967;25:45–75.
- Tallgren A. The reduction in face height of edentulous and partially edentulous subjects during long-term denture wear. A longitudinal roentgenographic cephalometric study. *Acta Odontol Scand* 1966;24:195–239.
- Tallgren A. The effect of denture wearing on facial morphology. A 7-year longitudinal study. *Acta Odontol Scand* 1967;25:563–592.
- Tan WL, Wong TL, Wong MC, Lang NP. A systematic review of post-extraction alveolar hard and soft tissue dimensional changes in humans. *Clin Oral Implants Res* 2012;23(suppl):s1–s21.
- Van der Weijden F, Dell'Acqua F, Slot DE. Alveolar bone dimensional changes of post-extraction sockets in humans: A systematic review. *J Clin Periodontol* 2009;36:1048–1058.
- Avila-Ortiz G, Elangovan S, Kramer KW, Blanchette D, Dawson DV. Effect of alveolar ridge preservation after tooth extraction: A systematic review and meta-analysis. *J Dent Res* 2014;93:950–958.
- Milinkovic I, Cordaro L. Are there specific indications for the different alveolar bone augmentation procedures for implant placement? A systematic review. *Int J Oral Maxillofac Surg* 2014;43:606–625.
- Stein RS. Pontic-residual ridge relationship: A research report. *J Prosthet Dent* 1966;16:251–285.
- Hochman MN, Chu SJ, Tarnow DP. Maxillary anterior papilla display during smiling: A clinical study of the interdental smile line. *Int J Periodontics Restorative Dent* 2012;32:375–383.